

Tumor budding as a new histological parameter in the metastasis of colorectal cancer

Ustymowicz W. ^{A-F}

Department of General Pathomorphology, Medical University of Białystok, Poland

A - Conception and study design; **B** - Collection of data; **C** - Data analysis; **D** - Writing the paper; **E** - Review article; **F** - Approval of the final version of the article; **G** - Other (please specify)

ABSTRACT

Introduction: The presence of tumor budding, i.e., single cancer cells or a nest of poorly differentiated cells at the front of tumor invasion appears to be a new histopathological indicator of increased aggressiveness of colorectal carcinoma.

Purpose: The aim of this work was a retrospective evaluation of the invasion front (tumor budding, vascular invasion, and lymphocytic infiltration) in postoperative biopsies of patients with colorectal carcinoma and analysis of the 5-year survival.

Materials and methods: The study was based on the material received after surgical treatment of 164 patients with colon cancer. Tissue was obtained directly following tumor resection, fixed in 10% formaldehyde and embedded in paraffin blocks using a routine method by melting with paraffin at a temperature of 56° C. These samples were then routinely stained with haematoxylin and eosin and underwent a histopathological evaluation, with particular attention being paid to the invasion front

of the tumor. The immunohistochemical expression of cytokeratin 20 was also evaluated using anti-human CK20 monoclonal antibody (clone Ks.20.8, Dako, Poland).

Results: Tumor budding was found in 124 out of 164 patients. Statistical analysis showed a correlation between the presence of tumor budding TB and depth of invasion (pT), lymph node metastasis, distant metastasis, lymphocytic infiltration, and vascular invasion. The cumulative five-year survival correlated with the lack of tumor budding and vascular invasion, as well as a decrease in lymphocytic infiltration.

Conclusion: The results suggest that budding, angioinvasion and lymphocytic infiltration can be considered as independent prognostic and predictive factors in colon cancer.

Keywords: Colon cancer, 5-year survival

DOI:

***Corresponding author:**

Wiktoria Ustymowicz, MD
Department of General Pathomorphology
Medical University of Białystok
ul. Waszyngtona 13, 15-269 Białystok, Poland
Tel:+48 85 7485942, fax; +48 85 7485996
e-mail:wiktoriaustymowicz@gmail.com

Received: 25.10. 2018

Accepted: 27.12.2018

Progress in Health Sciences

Vol. 8(2) 2018 pp 118-123

© Medical University of Białystok, Poland

INTRODUCTION

Recent clinico-pathological studies concerning prognostic factors in colorectal cancer are increasingly focused on the budding observed in tumor invasion front (tumor budding) as a potential prognostic factor in colorectal cancer [1]. The authors suggest the pathologists to implement an assessment of budding in the tumor invasion front into their daily routine histopathological diagnosis [2]. The presented data show that the presence of buds in tumor invasion front is associated with poor prognosis, vascular invasion, lymph node metastasis and distant metastasis [3].

Budding in the invasion front, however, is not entirely a new finding. Already in 1920, it was described by Broders [4] as undifferentiated cells in the invasion area of the lip. Broders determined four degrees of budding, depending on the proportion of undifferentiated cancer cells. He also observed the relationship between grade and prognosis. In 1987, Jass et al. [3] suggested categorisation depending on growth pattern, dividing rectal tumours into an expanding type and an infiltrating type [2,3]. They noted that glands at the advancing edge of adenocarcinoma were often disorganized and of a higher grade than the adenocarcinoma was predominantly. In 1989 Morodomi et al [5] first used the term "tumor budding", defined as the presence of single isolated undifferentiated cancer cell or as clusters of five or more cancer cells forming microtubular cancerous glands scattered in the stroma at the invasive margin of colorectal cancer. In 1993 Hase et al [6] redefined tumor budding as isolated single cancer cells or clusters of around five or fewer cancer cells forming a trabecular or microtubular architecture.

PURPOSE

The aim of our study was to retrospectively analyze the relationship between survival time of patients with histological markers of colorectal cancer aggressiveness in the invasion front. The particular emphasis was put on budding tumor presence according to the criteria of Morodomi et al. [5], lymphocytic infiltration according to the criteria of Jass et al. [7], as well as vascular invasion (lymphatic and venous invasion).

MATERIALS AND METHODS

The research was undertaken on a group of 164 patients with colorectal cancer treated surgically in the Second Department of Gastroenterological Surgery, Medical University of Białystok, Department of Surgery, Provincial Hospital J. Sniadeckiego in Białystok. Patients with familial polyposis following other malignant disease, or with inflammatory changes were not included in the study. The median age was 70 years, with a range of 32 to 89 years. 93 patients were male and 71 female. 92 tumors were located in the colon and 71 in the rectum. As many as 133 cancers do

not produce mucous while the other 27 had mucous component in their weaving. 146 tumors were histologically moderately differentiated and only 8 poorly differentiated. Lymph node metastases were observed in 78 cases, while distant metastasis to the liver and lungs was noted in 35 cases.

Clinical information

The group of patients was clinically monitored over a **60-month** period. The patient follow-up examination was conducted every six months, including abdominal ultrasound examination, CT and colonoscopy. Local recurrence around the post operative scar was confirmed histopathologically. Lymph node metastasis was confirmed in the post-operative material and distal (hepatic, pulmonum) metastases was confirmed by ultrasound-guided fine-needle aspiration cytology.

Evaluation of the parameters in the tumor invasion front

Tissue specimens were collected immediately after tumor removal, fixed in 10% buffered formaldehyde solution and embedded in paraffin. Hematoxylin-eosin-stained sections were examined according to the TNM classification, WHO histological classification.

The special attention was paid to the tumor budding, lymphocytic infiltration at the invasion front and vascular invasion.

Method of determining tumor budding (microtubular cancer clusters and undifferentiated cancer cells)

Budding was evaluated according to the criteria of Morodomi et al [5]. For each case study all H&E tumor slides were independently assessed by two pathologists (A.K. and K.G-U.), who were blinded to outcomes. Tumor budding was evaluated on Olympus CX41 microscope. **Median** number of slides per case available for analysis was 5. All the slides were examined in 5 different areas at 400 x magnification and the mean budding count was computed.

-TB (-) the mean count ≤ 1 considered negative, and
-TB (+) the mean count > 1 or more was positive

Method of Determining Inflammatory lymphocytic infiltration

Inflammatory lymphocytic infiltration was evaluated according to the Jass classification [7].

Lymphocytic infiltration was graded as: 0 - lack, 1 - weak, 2 - moderate, 3 - strong.

Immunohistochemical analysis

Reassessment of the budding was made in the preparations stained with cytokeratin 20 (clone Ks20.8, Dako, Poland).

For the purpose of coloring the preparations previously embedded in paraffin, tissue material was cut on the microtome into 4 μ m-thick sections. Immunohistochemical reactions were carried out in the camera Autostainer Link (Dako, Poland), with the use

of monoclonal mouse anti-human CK20 antibody (clone Ks20.8, Dako, Poland) and detection system Dako EnVision TM FLEX, High pH (Dako, Poland).

Similarly to the H&E staining, the same criteria was chosen for evaluating the budding. For statistical analysis average values of both the budding in H&E staining and the one with the use of cytokeratin 20 were used.

Ultimately two groups were determined, which were used for statistical analysis.

-TB (-) the mean count ≤ 1 considered poor, and

-TB (+) the mean count > 1 or more was strongly positive

Method of vascular invasion evaluation

Lymphatic and venous invasions were examined, and assessed together with vascular invasion as in Guzińska-Ustymowicz [8].

Statistical analysis.

The Chi-square test was used for statistical analysis. Survival curve was estimated with the use of the Kaplan-Meier method and compared in the long-

rank test. A p-value smaller than 0.05 was considered statistically significant. Gaps in data were removed in pairs.

RESULTS

In the studied group of 164 patients with colorectal cancer 124 cases (75.6%) were observed with tumor invasion front budding. No relationship was found between the presence of tumor budding in front of the invasion and the age and sex of patients, as well as the location, histological type and degree of malignancy of colon cancer.

It was observed that the presence of budding is associated with pT (p=0.001) characteristic. The greater degree of local tumor advancement, the greater the budding in the tumor invasion front. Moreover, the presence of budding was more often identified in patients with metastases to the current regional lymph nodes (p = 0.000) and metastasis to distant organs (p = 0.005) than patients without metastasis (Table 1).

Table 1. Clinicopathological parameters and tumor budding at the front of colorectal cancer

Variables		Tumor budding		p value
		Absent (n=40)	Present (n=124)	
Age	<60	8 (20%)	32 (80%)	0.490
	≥ 60	31 (25.4%)	91 (74.6%)	
Gender	Male	24 (25.8%)	69 (74.2%)	0.631
	Female	16 (22.5%)	55 (77.5%)	
Localization	Colon	20 (21.7%)	72 (78.3%)	0.459
	Rectum	19 (26.8%)	52 (73.2%)	
Adenocarcinoma type	Non mucinosum	29 (21.8%)	104 (78.2%)	0.093
	Mucinosum	10 (37%)	17 (63%)	
Grade of histological malignancy	Moderately differentiated	35 (23.9%)	111 (76.1%)	0.458
	Poorly differentiated	1 (12.5%)	7 (87.5%)	
Depth of invasion	pT1	2 (50%)	2 (50%)	0.001
	pT2	7 (63.6%)	4 (36.4%)	
	pT3	29 (23%)	97 (77%)	
	pT4	1 (9.1%)	10 (90.1%)	
Lymph node metastasis	Absent	36 (42.3%)	49 (57.7%)	0.000
	Present	3 (3.8%)	75 (96.2%)	
Distant metastasis	Absent	33 (28%)	85 (72%)	0.005
	Present	2 (5.7%)	33 (94.3%)	
Lymphocytic infiltration	0	4 (8.7%)	42 (91.3%)	0.000
	1	9 (13.2%)	59 (86.8%)	
	2	11 (35.5%)	20 (64.5%)	
	3	15 (83.3%)	3 (16.7%)	
Vascular invasion	Absent	38 (53.5%)	33 (46.5%)	0.000
	Present	2 (2.1%)	91 (97.8%)	

The overall cumulative 5-year survival for 103 patients with colorectal cancer was 32%. The percentage of patients differed significantly depending on the presence of buds (P <0.000). In patients with positive tumor budding (TB +) in front of tumor invasion overall survival was significantly shorter than

in patients with negative budding (TB -).

The presence of budding in tumor invasion front strongly correlated with decreasing inflammatory infiltrate in this area.

By weak inflammatory infiltration or lack of it, the budding was observed in total of 101 cases. Only

in 23 cases buds were present where the intensity of the inflammatory infiltrate was moderate and strong (Table 1, Fig.1). At the same time it was observed that the overall survival time was longer in patients with the presence of inflammatory infiltrate in the invasion front.

93 cases were observed with tumor cell

emboli in the blood vascular invasion, 91 of which correlated with budding in the front of tumor invasion. Analysis of the cumulative 5-year survival of patients with colorectal cancer showed the relation between the presence of the tumor cell emboli in the vessels and a shorter survival time of the patients.

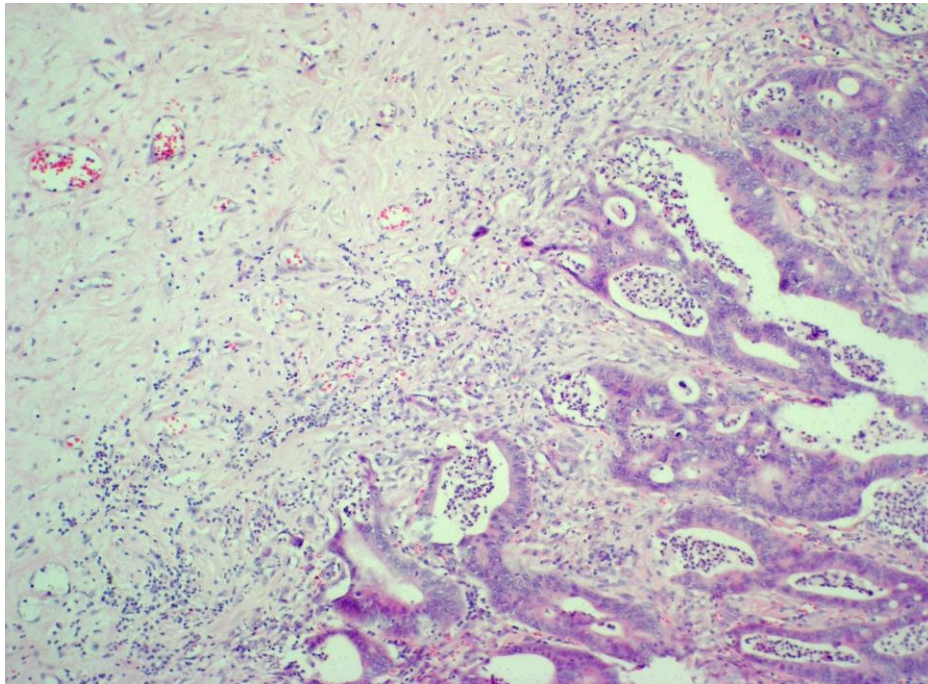


Figure 1. Tumor budding at the front invasion of colorectal cancer

DISCUSSION

Colorectal cancer is one of the most common types of cancer in Western countries Fair for Poland. The mortality of colorectal cancer is ranked as the second in Western countries, and the third in Poland, amongst all cancers.

It seems that discovering the biological behavior of cancers, including colorectal cancer, is a major task for scientists. It has long been attempted to find markers visible in the histological picture which would allow the assessment of the behavior (progression) of tumors [2,3,4,9-12].

Recent studies indicate the usefulness of the assessment of budding in the invasion front of colorectal cancer as a predictive factor in these patients [8]. Our research is the first analysis of the relationship of histopathologic parameters in invasion front of colorectal cancer budding, lymphocytic infiltration and venous invasion in with the 5 year survival of Polish patients with colon cancer.

In the group of analyzed patients 124 out of 164 were observed with budding in the front of tumor invasion. Similarly to other authors we did not find any relationship between age, gender and location of the tumor, histological type or malignancy grade. The percentage of cases with budding increased with the growing tumor infiltration depth. The highest percentage of cases with budding were observed in pT4

tumors. It was also noted that the budding was also present in pT1 tumors in 50% and pT2 in 36.4% of cases. Other authors have similar observations. [6,7,8,11,12].

Out of 78 cases with diagnosed metastases to the lymph nodes in as many as 75 (96.2%) we found the presence of budding. In addition, we have shown the correlation between the presence of distant metastasis and extensive budding. In as many as 94.3% of cases with distant metastases the budding was present. Similarly, Hase et al. [6] examined 663 patients with CRC (colorectal cancer) for tumor budding, and suggested that tumor budding is an important prognostic factor in patients with CRC [6].

Tumor budding at the front of invasion is a recent widely studied parameter, possibly indicating an increased aggressiveness of a given tumor, along with a decreased 5 year survival in patients with colorectal carcinoma. In the studies which have been published, tumor budding at the front of invasion has been associated with a strong tendency for metastases in colorectal carcinoma. It is consistent with the results obtained in our study. Morodomi et al. [5] were the first to present results based on the analysis of pre-operative biopsies, where the intensity of tumor budding at the front of invasion was assessed. The results of our studies suggest that the intensity of tumor budding strongly correlates with the presence of lymph node metastases, distant metastases, venous invasion, and

loss of lymphatic infiltration.

Some studies examined the relationship between the presence of vascular invasion and tumor budding in pT1 and pT2 colorectal cancers [13,14,15,16,17]. This author described a group of patients with well-differentiated colorectal cancers and concluded that the evaluation of the front of invasion (vascular invasion and tumor budding) in histopathological samples should be a routine part of the pathomorphological diagnosis, since these two parameters are indicators of lymph node metastasis [25]. The findings of the present study imply a strong association between the presence of tumor budding in pre-operative material and the appearance of proximal and distal metastases. Moreover, vascular invasion was strongly-associated with the presence of tumor budding. Similarly to our study.

Ueno et al. [18,20] examined 638 patients with rectal cancer and concluded that tumor budding would be a good index to estimate the aggressiveness of rectal cancer. Other authors have noted the usefulness of evaluating tumor budding in association with the presence of metastases and life expectancy [6,15-20]. Tanaka et al [21] described that the appearance of tumor budding in Stage II, T3 colon cancer indicated a high risk of tumor recurrence after curative budding surgery. They found tumor budding to be present in all three cases where there was local recurrence.

Our results suggest the relationship between the presence of a compound of budding in the tumor invasion front, and the presence of lymph node metastases, distant metastases, as well as survival of patients. It was also proven by other authors [5,6,22-25].

The work presented by Japanese researchers shows the usefulness of the assessment of budding in colon cancers in pT1 stage.

Masaki et al. [10] suggest that actual number of tumor budding units may be useful in the decision making for patient-oriented treatment of T1 colorectal carcinomas. Also, Suzuki A, et al. [9] suggested that the presence of infiltrates in the lymph vessels and budding of the tumor are predictive factors for the emergence of metastases to the lymph nodes and distant metastases in patients with colorectal cancer in the degree of pT1. This is consistent with our results. Ogawa et al. [10] analyzed the presence of buds in early stages of colon cancers are classified them into polypoid and non-polypoid growth types. They noted that tumor budding makes contribution to a greater progression in non-polypoid growth than in polypoid carcinomas, with possible involvement of lymph node metastasis. Yamauchi et al. [11] suggested that tumor budding is a useful predictor for lymph node metastasis in T1 colorectal cancer. In our research we observed metastasis to the lymph nodes in 78 cases, of which 75 (96.2%) have shown the presence of budding. While in 35 cases with distant metastasis budding was present in 33 cases. Both our observations and the ones of other authors suggest relationship between budding and metastasis. At the same time in patients with budding

in 85 cases there were no distant metastases, and in 49 no lymph node metastases. Like Wang et al. [14], who examined 128 patients with T3N0M0 with colorectal cancer finding 45% of patients with a high degree of budding (according to the adopted criteria) and 55% with a low degree. High budding was associated with an infiltrative growth pattern and lymphovascular invasion. They observed that five-year cancer-specific survival was significantly poorer in the high compared with the low budding groups. Therefore, they suggested that the budding can be recognized as a prognostic marker to evaluate the risk of recurrence. In our study survival for patients with positive budding was significantly shorter than for the patients with negative budding.

Our analysis also included an assessment of the presence of tumor cell emboli of the tumor cells in lymph and venous vessels. We observed a strong correlation of the presence of congestion (venous invasion) with budding. This is consistent with the findings of others [15].

Nakamura et al. [16] compare the total of 200 Patients with Stage II disease with low-grade or high-grade tumor budding with that of 226 patients who had colon cancer Stage III. Univariate analysis revealed that serosal surface involvement and tumor budding were significantly related to survival. And that liver and peritoneal metastases were more frequent in patients with high-grade tumor budding than in those with low-grade.

Some scientists analyzed 244 patients with colorectal cancers found in stage III and found that the presence of budding in front of tumor invasion was associated with a greater potential for malignancy. In another study Choi et al. [15] studied a group of 87 patients with colorectal cancer pT1 evaluating budding and venous invasion, stating that the budding was an independent risk factor for lymph node metastases.

In our study we analyzed the presence of lymphatic infiltration in the front of tumor invasion, watching the relationship between growth and decline in the degree of infiltration of budding in the tumor invasion front. Such results seem to be in accordance with the ones recently described by scientists as so-called anti- and pro-tumorigenic phenomenon in the tumor invasion front [17].

In conclusion, can be considered as the exponent of the aggressiveness of colorectal cancer and a predictive factor related to survival time of patients with colon cancer. The results presented by other authors and us suggest that budding in front of tumor invasion may be classified as factors strongly associated with metastasis of colon cancer.

Conflicts of interest

The authors have no conflicts of interest.

REFERENCES

1. Ueno H, Murphy J, Jass JR, Mochizuki H, Talbot IC. Tumor budding as an index to estimate the

- potential of aggressiveness in rectal cancer. *Histopathology*. 2002 Feb;40(2):127-32.
- Jass JR, Love SB Northover JMA. A new prognostic classification of rectal cancer. *Lancet*. 1987 Jun 6;1(8545):1303-6
 - Jass JR, Atkin WS, Cuzick J, Bussey HJ, Morson BC, Northover JM, Todd IP. The grading of rectal cancer: historical perspectives and a multivariate analysis of 447 cases. *Histopathology* 1986 May;10(5):437-59.
 - Broders AC. Squamous-cell epithelioma of the lip. A study of five hundred and thirty-seven cases. *J Am Med Assoc*. 1920;74(10):656-64.
 - Morodomi T, Isomoto H, Shirouzu K, Kakegawa K, Irie K, Morimatsu M. An index for estimating the probability of lymph node metastasis in rectal cancers. Lymph node metastasis and the histopathology of actively invasive regions of cancer. *Cancer*. 1989 Feb 1;63(3):539-43.
 - Hase K, Shatney C, Johnson D, Trollope M, Vierra M. Prognostic value of tumor „budding” in patients with colorectal cancer. *Dis Colon Rectum*. 1993 Jul;36(7):627-35.
 - Jass JR. Lymphocytic infiltration and survival in rectal cancer. *J Clin Pathol*. 1986 Jun;39(6):585-9.
 - Guzińska-Ustymowicz K. Aggressive and non-aggressive tumor budding in colorectal cancers. In: *Tumor budding in colorectal cancer* (Muto T, Mochizuki H, Masaki T (eds.). New York: Nova Biomedical Books; 2006. pp 105-16,.
 - Jass JR, Ajioka Y, Allen JP, Chan YF, Cohen RJ, Nixon JM, Radojkovic M, Restall AP, Stables SR, Zwi LJ. Assessment of invasive growth pattern and lymphocytic infiltration in colorectal cancer. *Histopathology*. 1996 Jun;28(6):543-8.
 - Masaki T, Matsuoka H, Sugiyama M, Abe N, Sakamoto A, Atomi Y. Actual number of tumor budding as a New tool for the individualization of treatment of T1 colorectal carcinoma. *J Gastroenterol Hepatol*. 2006 Jul;21(7):1115-21.
 - Suzuki A, Togashi K, Nokubi M, Koinuma K, Miyakura Y, Horei H, Lefor AT, Yasuda Y. Evaluation of venous invasion by Elastic van Gieson stain and tumor budding predicts local and distant metastases in patients with T stage colorectal cancer. *Am J Surg Pathol* 2009 Nov; 33(11):1601-7.
 - Ogawa T, Yoshida T, Tsuruta T, Tokuyama W, Adachi S, Kikuchi M, Mikami T, Saigenji K, Okayasu I. Tumor budding is predictive of lymphatic involvement and lymph node metastases in submucosal invasive colorectal adenocarcinomas and in non-polypoid compared with polypoid growths. *Scand J Gastroenterol* 2009;44(5):605-14.
 - Yamauchi H, Togashi K, Kawamura YJ, Horie H, Sasaki J, Tsujinaka S, Yasuda Y, Konishi F. Pathological predictors for lymph node metastasis in T1 colorectal cancer. *Surg Today* 2008;38(10):905-10.
 - Wang LM, Kevans D, Mulcahy H, O’Sullivan J, Fennelly D, Hyland J, O’Donoghue D, Sheahan K. Tumor budding is a strong and reproducible prognostic marker in T3N0 colorectal cancer. *Am J Surg Pathol* 2009 Jan;33(1):134-41.
 - Choi DH, Sohn DK, Chang HJ, Lim SB, Choi HS, Jeong SY. Indications for subsequent surgery after endoscopic resection of submucosally invasive colorectal carcinomas: a prospective cohort study. *Dis Colon Rectum* 2009 Mar;52(3):438-45.
 - Nakamura T, Mitomi H, Kanazawa H, Ohkura Y, Watanabe M. Tumor budding as an index to identify High-risk patients with stage II colon cancer. *Dis Colon Rectum*. 2008 May;51(5):568-72.
 - Choi HJ, Park KJ, Shin JS, Roh MS, Kwon HC, Lee HS. Tumor budding as a prognostic marker in stage-III rectal carcinoma. *Int J Colorectal Dis*. 2007 Aug;22(8):863-8.
 - Ueno H, Mochizuki H, Shinto E, Hashiguchi Y, Hase K, Talbot IC. Histologic indices in biopsy specimens for estimating the probability of extended local spread in patients with rectal carcinoma. *Cancer*. 2002 Jun 1;94(11):2882-91.
 - Nakamura T, Mitomi H, Kikuchi S, Ohtani Y, Sato K. Evaluation of the usefulness of tumor budding on the prediction of metastasis to the lung and liver after curative excision of colorectal cancer. *Hepatogastroenterology*. 2005 Sep-Oct; 52(65): 1432-5.
 - Ueno H, Mochizuki H, Hatsuse K, Hase K, Yamamoto H. Indicators for treatment strategies of colorectal liver metastases. *Ann Surg*. 2000 Jan;231(1):59-66.
 - Tanaka M, Hashiguchi Y, Ueno H, Hase K, Mochizuki H. Tumor budding at the invasive margin can predict patients at high risk of recurrence after curative surgery for stage II, T3 colon cancer. *Dis Colon Rectum*. 2003 Aug;46(8):1054-9.
 - Masaki T, Matsuoka H, Sugiyama M, Abe N, Mori T, Atomi Y, Watanabe T, Nagawa H, Muto T. Budding as a useful determinant of the optimal treatment for T1 rectal carcinomas. *Hepatogastroenterology*. 2003 Mar;50(50): 388-91.
 - Okuyama T, Masathoshi O, Ishikawa H. Budding as a risk factor for lymph node metastasis in pT1 or pT2 well-differentiated colorectal adenocarcinoma. *Dis Colon Rectum* 2002 May;45(5):628-34.
 - Okuyama T, Oya M, Yamaguchi M. Budding (sprouting) as a useful prognostic marker in colorectal mucinous carcinoma. *Jpn J Clin Oncol*. 2002 Oct;32(10):412-6.
 - Lugli A, Kirsch R, Ajioka Y, Bosman F, Cathomas G, Dawson H, El Zimaity H, Fléjou JF, Hansen TP, Hartmann A, Kakar S, Langner C, Nagtegaal I, Pappa G, Riddell R, Ristimäki A, Sheahan K, Smyrk T, Sugihara K, Terris B, Ueno H, Vieth M, Zlobec I, Quirke P. Recommendations for reporting tumor budding in colorectal cancer based on the International Tumor budding Consensus Conference (ITBCC) 2016. *Mod Pathol* 2017 Sep;